



# **Acute Flaccid Myelitis (AFM)**

**Communicable Disease Control Section**

**Vaccine Preventable Disease**

# Presentation Overview

- What is AFM?
- Epidemiology
- Laboratory testing
- Surveillance and reporting to public health
- Resources

# What is Acute Flaccid Myelitis (AFM)?

- Acute Neurologic illness with focal limb weakness of unknown etiology
- Mostly seen in children but has been seen in some adults as well.
- Poliomyelitis-like presentation
- National surveillance initiated in 2014

# Clinical Presentation

- Sudden onset of arm or leg weakness, loss of muscle tone, and loss of reflexes are the most common symptoms.
- Other symptoms include:
  - facial droop/weakness
  - difficulty moving the eyes
  - drooping eyelids
  - difficulty with swallowing
  - slurred speech.
- Some patients have pain in their arms or legs or are unable to pass urine.
- MRI scan showing inflammation of the gray matter (nerve cells) in the spinal cord.
- Usually a fever and/or a respiratory illness before onset of neurological symptoms.
- Elevated white blood cell counts in spinal fluid.

# Clinical Presentation – Part 2

- The most severe symptom for AFM is respiratory failure due to weakness in muscles which effects breathing.
- An AFM suspect case should be in a healthcare setting that has ventilator support availability due to potential respiratory failure.

# Clinical Management

- Up to physician/provider caring for patient, but CDC does have clinical guidance on their website: <https://www.cdc.gov/acute-flaccid-myelitis/hcp/clinical-management.html>
- Suggested that clinicians should immediately consult with their local neurologists and/or infectious disease specialists for treatment and medical management decisions for any suspected AFM patient.

# Clinical Management – Limited Access

- The Siegel Rare Neuroimmune Association
- AFM Physician Consult and Support Portal

<https://wearesrna.org/living-with-myelitis/resources/afm-physician-support-portal/>

# What causes AFM?

- Enteroviruses (polio and non-polio)
- Adenovirus
- West Nile Virus and similar viruses
- Increase in 2014 coincided with national outbreak of enterovirus D68 (EV-D68)
- Increase in 2018 coincided with EV-D68 and EV-A71



# Prevention

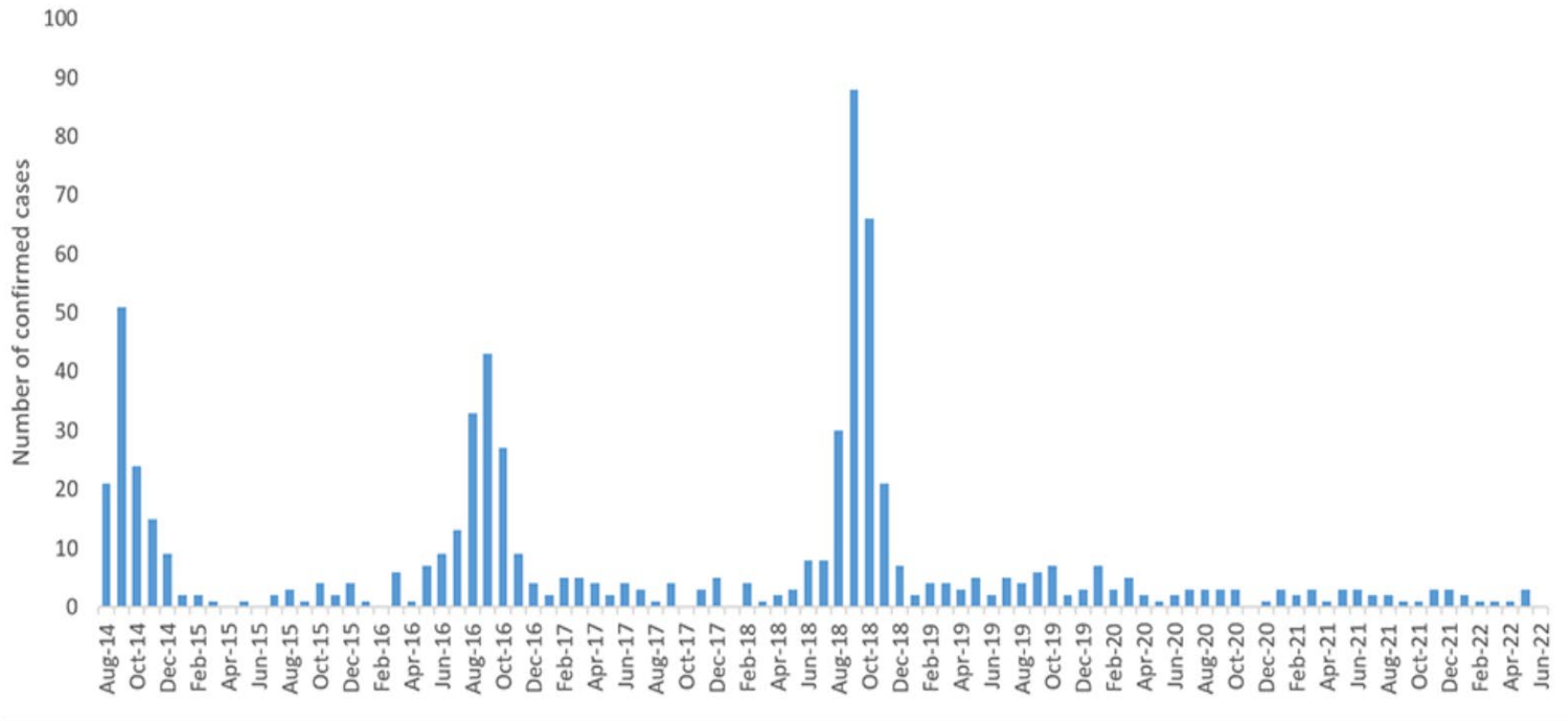
- No known definitive prevention for AFM
- Attempt to prevent other illness such as West Nile, EV-D68, etc.
- Proper handwashing
- Avoid contact with people who are sick
- Stay up to date on recommended vaccinations

# What can you do?

- LHD should educate the providers in their jurisdiction about AFM.
- Distribute AFM educational materials, memos, etc.
- Monitor local and US-wide trends of AFM cases.
- Clinicians should thoroughly and promptly report cases to public health and submit specimens as indicated.

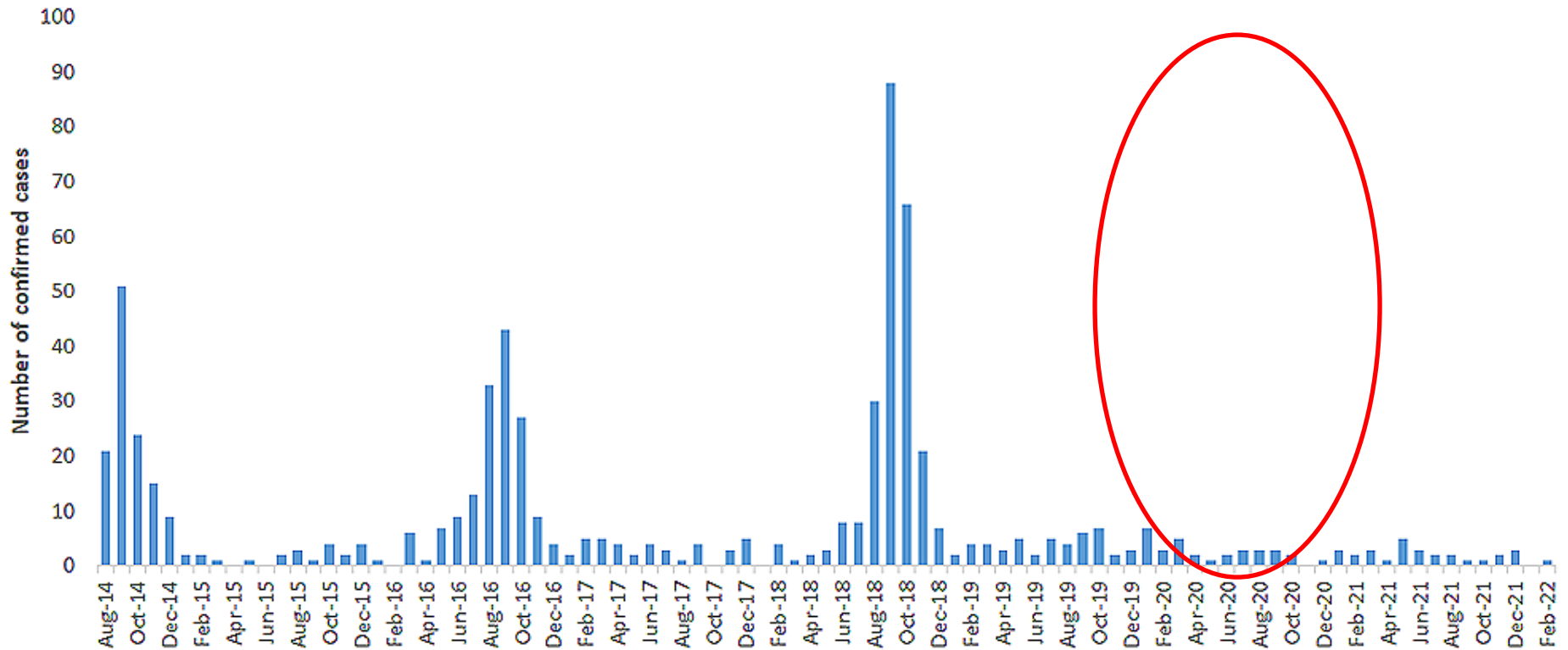
# AFM Surveillance - National 2014 - 2022

## Confirmed AFM cases by CDC



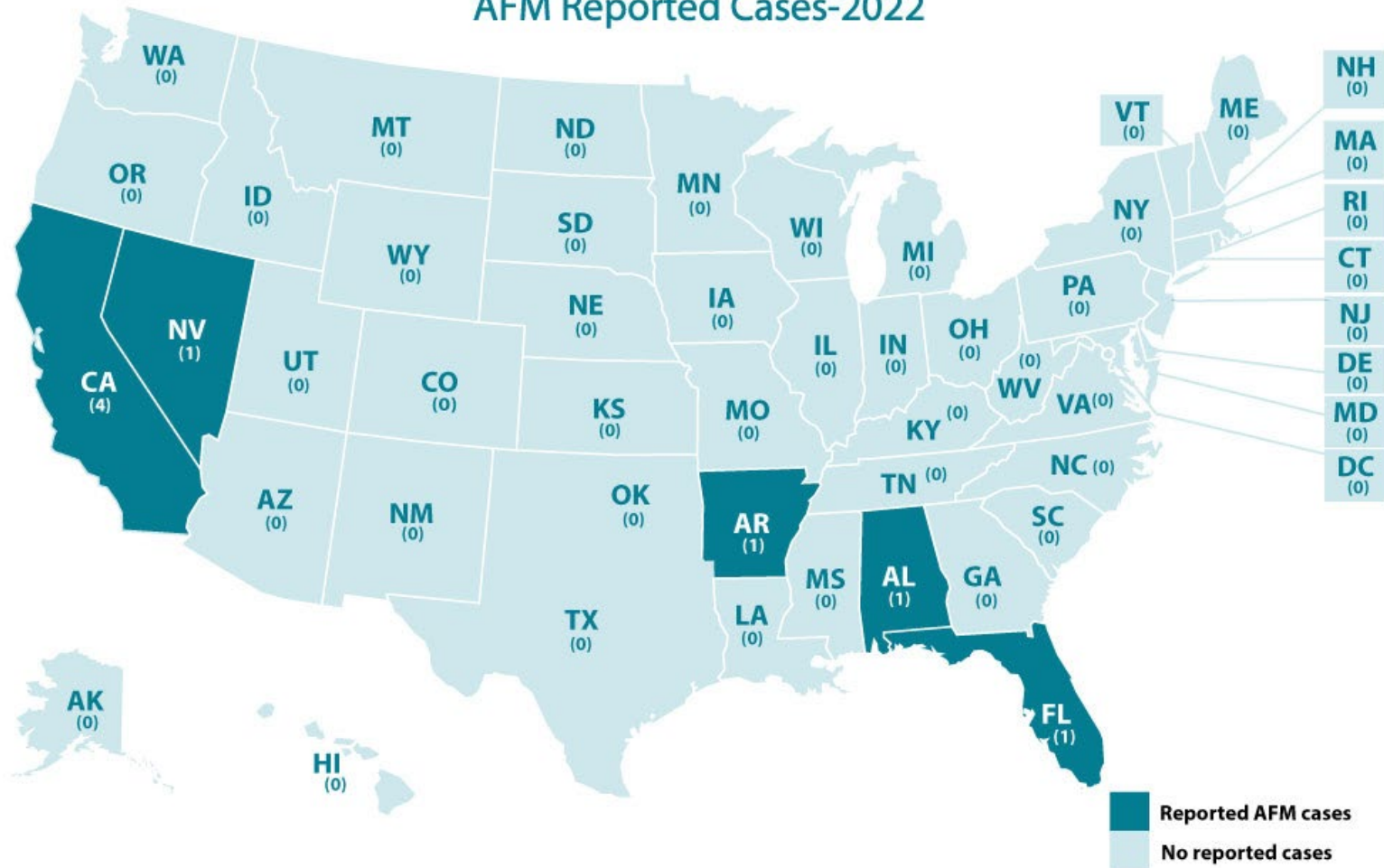
Source: CDC

# AFM Surveillance Histogram 2014 - 2022



# AFM Surveillance – 2022

AFM Reported Cases-2022



Source: CDC

# Illinois

<b>YEAR</b>	<b>PATIENTS UNDER INVESTIGATION (PUI) IN ILLINOIS*</b>	<b>CONFIRMED AFM CASES**</b>	<b>PROBABLE AFM CASES**</b>	<b>NOT CASES**</b>
2020	3	2 (One International Case)	0	0
2019	3	0	1	2
2018	18	9	2	7

# Clinical and Other Classification Criteria

## Clinical Criteria

- An illness with onset of acute flaccid\* weakness of one or more limbs, **AND**
- Absence of a clear alternative diagnosis attributable to a nationally notifiable condition.

*\* Low muscle tone, limp, hanging loosely, not spastic or contracted.*

## Other classification criteria

- Autopsy findings that include histopathologic evidence of inflammation largely involving the anterior horn of the spinal cord spanning one or more vertebral segments.

# Laboratory/Imaging criteria

## **Confirmatory laboratory/imaging evidence:**

- MRI showing spinal cord lesion with predominant gray matter involvement\* and spanning one or more vertebral segments, **AND**
- Excluding persons with gray matter lesions in the spinal cord resulting from physician diagnosed malignancy, vascular disease, or anatomic abnormalities.

## **Presumptive laboratory/imaging evidence:**

- MRI showing spinal cord lesion where gray matter involvement\* is present but predominance cannot be determined, **AND**
- Excluding persons with gray matter lesions in the spinal cord resulting from physician diagnosed malignancy, vascular disease, or anatomic abnormalities.

## **Supportive laboratory/imaging evidence:**

- MRI showing a spinal cord lesion in at least some gray matter\* and spanning one or more vertebral segments, **AND**
- Excluding persons with gray matter lesions in the spinal cord resulting from physician diagnosed malignancy, vascular disease, or anatomic abnormalities.

*\* Spinal cord lesions may not be present on initial MRI; a negative or normal MRI performed within the first 72 hours after onset of limb weakness does not rule out AFM. Terms in the spinal cord MRI report such as “affecting mostly gray matter,” “affecting the anterior horn or anterior horn cells,” “affecting the central cord,” “anterior myelitis,” or “poliomyelitis” would all be consistent with this terminology.*



# SURVEILLANCE Case Classifications

Case Classification	Description
Confirmed	Meets clinical criteria with confirmatory laboratory/imaging evidence, <b>OR</b> Meets other classification criteria.
Probable	Meets clinical criteria with presumptive laboratory/imaging evidence.
Suspect	Meets clinical criteria with supportive laboratory/imaging evidence, <b>AND</b> Available information is insufficient to classify case as probable or confirmed.

# Reporting Steps

1. Providers should report suspect AFM cases to the [local health department](#) (LHD). The case should also be entered into INEDSS by the provider/facility or LHD.
2. The LHD (in consultation with IDPH) will review the information to make sure the case criteria for reporting is met. (Acute flaccid limb weakness with spinal cord lesions in at least some gray matter spanning one or more spinal segments and exclude persons with lesions resulting from physician diagnosed malignancy, vascular disease, or anatomic abnormalities.)
3. The LHD should work with the provider to complete the [Patient Summary Form](#), obtain the MRI report, and neurology consult notes with images and submit them to IDPH.
4. A secure CDC web link for uploading images and records will be provided to the LHD and provider when a suspect case is reported.
5. The provider or local health department should enter the case in INEDSS as 'Acute Flaccid Myelitis.'

# Reporting Forms

- The following forms must be sent securely to IDPH (either directly or through the LHD) at 217-524-0962.
  - Patient Summary Form
  - MRI Report
  - Neurology consult notes
- **A copy of the patient summary form should ALSO be sent with laboratory specimens.**
- Forms can be found on the IDPH web portal a-z disease pages under “Acute Flaccid Myelitis” or at CDC’s website:  
<https://www.cdc.gov/acute-flaccid-myelitis/index.html>

**IDPH** web portal Home »  
ILLINOIS DEPARTMENT OF PUBLIC HEALTH

Home Applications ▾ Communities ▾ Personnel Worksite Wellness ▾

**IDPH WEB PORTAL**  
**RESOURCES**

- CMS Service Desk
- IDPH Intranet
- Outlook Web Access
- eTime
- SIREN
- TeamViewer Remote Assistance Launcher
- Workforce Development Training

**SIREN** - State of Illinois Rapid Electronic Notification  
SIREN provides regional, State, and Federal partners with a comprehensive solution.

**I-TRAIN**  
The one-stop-shop for public health workforce learning needs!

**Communicable Disease Topics from A to Z**  
This website constitutes the CD Section infectious disease A to Z information is periodically updated based upon evolving standards



# Specimen Collection & Laboratory Testing

- Collect specimens as early as possible in cases where AFM is suspect.

- Suggested specimens to be collected:

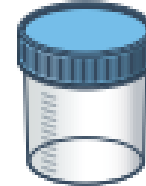- cerebrospinal fluid (CSF)
- blood (serum and whole blood),
- Stool
- AND a nasopharyngeal aspirate, nasopharyngeal wash, or nasopharyngeal swab with lower respiratory specimen if indicated,
- OR an oropharyngeal swab




CSF



Serum



Stool



NP swab

- Laboratories should work with IDPH lab to ensure proper collection and submission. Additional instructions can be found on CDC's website: <https://www.cdc.gov/acute-flaccid-myelitis/hcp/specimen-collection.html>
- Specimens must be sent to an IDPH lab with an authorization number that the LHD generates on the webportal.

# LHD - 60-day follow up

- Obtain additional medical records and submit them to IDPH/CDC
  - a. Admission notes/History and Physical
  - b. Infectious disease consultation notes
  - c. Additional MRI reports and images
  - d. Diagnostic lab reports
  - e. Vaccination records
  - f. Discharge summary
  - g. EMG report (if done)
- The LHD will complete the 60 day follow up interview with the parent/guardian (found on the back of the [patient summary form](#)) and submit this to IDPH (Fax or secure email; IDPH will enter this into CDC Redcap project)

# LHD – 6 and 12 Month Follow ups

**6 and 12 month Follow ups are being discontinued in cases beginning in 2022 and going forward.**

**6 Months and 12 Months after onset follow ups were previously done on all cases. You no longer will be asked to do this.**

# Resources

- CDC 2020 webinar:  
<https://www.cdc.gov/acute-flaccid-myelitis/hcp/clinicians-health-departments/webinar-2020.html>
- FAQ: <https://www.cdc.gov/acute-flaccid-myelitis/hcp/faqs.html>

# Resources

- Standardized Case Definition for Acute Flaccid Myelitis: <https://ndc.services.cdc.gov/case-definitions/acute-flaccid-myelitis-2020/CDC>
- AFM for Clinicians and Health Departments: <https://www.cdc.gov/acute-flaccid-myelitis/hcp/clinicians-health-departments.html>
- AFM Resources and References: <http://www.cdc.gov/acute-flaccid-myelitis/references.html>
- CDC Specimen Collection Instructions: <http://www.cdc.gov/acute-flaccid-myelitis/hcp/instructions.html>
- Illinois Department of Public Health Web Portal: [https://dph.partner.illinois.gov/communities/communicabledisease/CDAZ/Pages/Myelitis%20Acute%20Flaccid%20\(Acute%20Neurological%20Illness%20with%20Limb%20Weakness\).aspx](https://dph.partner.illinois.gov/communities/communicabledisease/CDAZ/Pages/Myelitis%20Acute%20Flaccid%20(Acute%20Neurological%20Illness%20with%20Limb%20Weakness).aspx)
- AFM Surveillance at CDC: <http://www.cdc.gov/acute-flaccid-myelitis/afm-surveillance.html>
- Siegel Rare Neuroimmune Association (SRNA) <https://wearesrna.org/living-with-myelitis/resources/afm-physician-support-portal/>



# Questions



# References

- Ayscue, P, Van Haren, K., Sheriff, H, et al. Acute Flaccid Paralysis with Anterior Myelitis, California, June 2012-June 2014. MMWR Morb Mortal Wkly Rep 2014; 63 (40);903-906. DOI: <https://www.cdc.gov/mmwr/preview/mmwrhtml/mm6340a6.htm#:~:text=by%20the%20report%3F-A%20total%20of%2023%20cases%20of%20AFP%20with%20anterior%20myelitis,D68%20from%20upper%20respiratory%20specimens.>
- Division of Viral Diseases, National Centers for Immunization and Respiratory Diseases, CDC; Division of Vector-Borne Diseases, et al.; Notes from the Field: Acute Flaccid Myelitis Among Persons Aged  $\leq 21$  Years — United States, August 1–November 13, 2014. MMWR Morb Mortal Wkly Rep 2015; 63(53);1243-1244. DOI: <https://www.cdc.gov/mmwr/preview/mmwrhtml/mm6353a3.htm>
- Shah MM, Perez A, Lively JY, et al. Enterovirus D68-Associated Acute Respiratory Illness — New Vaccine Surveillance Network, United States, July–November 2018–2020. MMWR Morb Mortal Wkly Rep 2021;70:1623–1628. DOI: <http://dx.doi.org/10.15585/mmwr.mm7047a1external icon>.
- Kidd S, Yee E, English R, et al. National Surveillance for Acute Flaccid Myelitis — United States, 2018–2020. MMWR Morb Mortal Wkly Rep 2021;70:1534–1538. DOI: <http://dx.doi.org/10.15585/mmwr.mm7044a2external icon>.
- Kidd S, Lopez A, Nix WA, et al. *Vital Signs*: Clinical Characteristics of Patients with Confirmed Acute Flaccid Myelitis, United States, 2018. MMWR Morb Mortal Wkly Rep 2020;69:1031–1038. DOI: <http://dx.doi.org/10.15585/mmwr.mm6931e3external icon>.
- Lopez A, Lee A, Guo A, et al. *Vital Signs*: Surveillance for Acute Flaccid Myelitis — United States, 2018. MMWR Morb Mortal Wkly Rep 2019;68:608–614. DOI: <http://dx.doi.org/10.15585/mmwr.mm6827e1external icon>.
- McKay SL, Lee AD, Lopez AS, et al. Increase in Acute Flaccid Myelitis — United States, 2018. MMWR Morb Mortal Wkly Rep 2018;67:1273–1275. DOI: <http://dx.doi.org/10.15585/mmwr.mm6745e1external icon>.
- Bonwitt J, Poel A, DeBolt C, et al. Acute Flaccid Myelitis Among Children — Washington, September–November 2016. MMWR Morb Mortal Wkly Rep 2017;66:826–829. DOI: <http://dx.doi.org/10.15585/mmwr.mm6631a2external icon>.
- Iverson SA, Ostdiek S, Prasai S, et al. *Notes from the Field*: Cluster of Acute Flaccid Myelitis in Five Pediatric Patients — Maricopa County, Arizona, 2016. MMWR Morb Mortal Wkly Rep 2017;66:758–760. DOI: <http://dx.doi.org/10.15585/mmwr.mm6628a4external icon>.



**THANK YOU**

**COMMUNICABLE DISEASE CONTROL SECTION  
VACCINE PREVENTABLE DISEASE**

**217-782-2016**

**[WWW.DPH.ILLINOIS.GOV](http://WWW.DPH.ILLINOIS.GOV)**